

Forehead Flap For Simultaneous Nose and Face Reconstruction

*O.M. Fasika, *A.O. Malomo,
**O.G.B. Nwaorgu, *O.O.
Adekunle,* A.J. Bolajoko,
and ***A.E. Obiechina.

*Departments of Surgery,
**Otorhinolaryngiology and
***Oral and Maxillofacial
Surgery, University College
Hospital, Ibadan, Nigeria.

Correspondence to:

Dr. O.M. Fasika

Department of Surgery
University College Hospital,
Ibadan, Nigeria.

Advanced facial malignancies and extensive tissue loss of the face from other causes such as trauma require reconstruction. When this involves the nose, the forehead flap comes in very handy. This paper presents and discusses modifications of forehead flap transfer with particular reference to extending it to cover both the nose and adjacent structures simultaneously. This method of reconstruction reduces the incidence of morbidity and it is recommended.

Keywords : *flap, forehead, nose, face reconstruction, superficial temporal artery, dermatofibrosarcoma, basal cell carcinoma.*

The use of the forehead flap for nose reconstruction is one of the oldest applications of the flap transfer techniques. The works of Conway et al¹ and Corso² have clarified its vascular anatomical basis.

The conventional forehead flap extends from the lateral (sideburn) area to a point above the outer end of the opposite eyebrow, thus providing sufficient tissue both for nose construction and the flap's pedicle.

This report describes modifications of the conventional forehead flap, used for facial repair as well as the simultaneous coverage of defects of the nose and adjacent structures.

Case Reports

Case 1

Mr. Y.O. (Hosp. No 845582) aged 36 years, presented with a recurrent dermatofibrosarcoma involving the nasion and the nose-bridge, 10 years after the excision of a left sided cheek and nose tumour.

A wide excision down to nasal bones and the cartilage was performed. A forehead flap based on the supratrochlear artery was applied and a skin graft was used to cover the flap donor site. The dog ear was returned to the donor site two weeks later.

At the last follow up two months afterwards, patient remained satisfied with the cosmetic result, and was recurrence free.

Case 2

Miss E.V. (Hosp. No. 866311) was a 22

year old suffering from a squamous cell carcinoma involving the upper lip, alveolus, palate and nose. Excision involved the upper lip and nose down to both maxillary antra and hard palate. Nasal reconstruction was with a left laterally based inverted 'U' shaped forehead flap with its tip just above the right eyebrow. The lip was reconstructed with a graft-lined pedicled deltopectoral flap based on the second and third intercostal perforators of the left internal mammary artery. The latter flap was divided with part of it being used for oral lining and the other returned to the chest.

The forehead flap however suffered tip necrosis which necessitated further stages of transfer.

Case 3

Mr. A.T. (Hosp. No. 58305) was 68 year old man who presented with an advanced squamous cell carcinoma of the right infraorbital region (Figure 1).

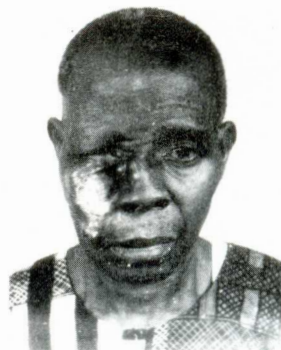

Figure 1: Case 3, Preop. Advanced Squamous Cell Carcinoma, Right Infraorbital region

Surgery confirmed the involvement of ipsilateral maxillary antrum, orbital floor and the right side of the nose.

A wide excision with orbital exenteration was performed and right lateral forehead flap was utilized to cover the defect (Figure 2). The oral component of the defect was lined using redundant skin (dog ear) from the inferior angle of the flap in the cheek area.

The tumour however recurred before radiotherapy and patient asked for a discharge shortly afterwards.

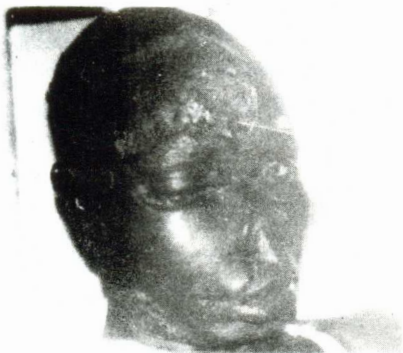

Figure 2: Case 3, Post-op, Repair of right cheek and nose defects with forehead and glabellar flaps

Case 4

Mr. O.R. (Hosp. No. 906024) aged 50 years was referred by the neurosurgical team on account of a scalp defect over a left frontal penetrating gun injury. A fascia lata dural graft covered by a medical forehead flap was transferred. Flap donor site was closed with a split skin graft.

Case 5

Mr. F.M. (Hosp. No. 904541) aged 66 years presented with a progressive left cheek lesion which on biopsy was reported as basal cell carcinoma (Figure 3). Tumour excision involved the nose, part of the nasal septum, medial third

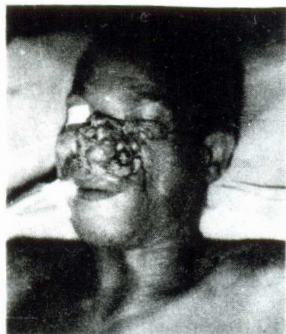

Figure 3: Case 5, Preop. Advanced basal cell carcinoma of left cheek involving nose.

of ipsilateral superior and inferior palpebrae, left cheek and ipsilateral half of super upper lip.

Repair was achieved with an inverted 'U' forehead flap based on the anterior (frontal) branch of the left superficial temporal artery. The right limb of the inverted 'U' was modelled to reconstruct the nose while the pedicle was spread out to cover adjacent left cheek and inferior palpebra



Figure 4: Case 5, Postop. Forehead flap repair of cheek and nose defects. The upper lip and donor forehead were resurfaced with skin grafts.

A "V-Y" flap each from left superior palpebral and naso-labial area were transferred to repair the superior palpebral and upper lip defects respectively. Split skin graft from the thigh was used to cover the forehead flap donor site and residual upper lip defect. Flap dog ear was trimmed three weeks later.

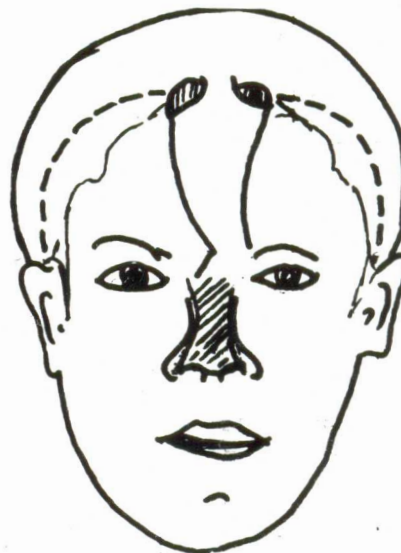


Figure 5: Extended midline flap. The donor site may be closed by advancing the edges through lateral extension incisions at hairline.

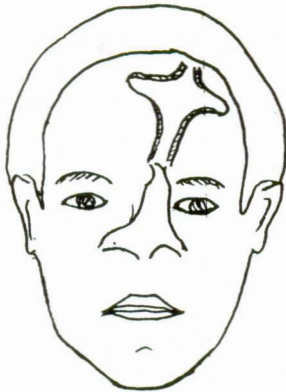


Figure 6: Seagull flap for external lining of the nose.

Discussion

Vascular injection studies have shown that the dynamic territory of the conventional forehead flap consists of four anatomical territories which belong to the two anterior branches of the superficial temporal arteries and the two supratrochlear arteries³. The extensive large diameter anastomoses of these vessels allow for the formation of an axial territory.

Several flaps can be raised based on one or more of the mentioned arteries. The conventional forehead flap is about 30cm long and 10cm wide (between the frontal hairline and the eyebrows). For a shorter length requirement, the elevation may be stopped above the contralesional eyebrow as we did in case 3 above.

Variations of forehead flap include:

- i. Midline forehead flap: The maximum width that permits direct closure is 3cm, Case 4 above is an example.
- ii. Extended midline flap⁴: See figure 5. This is narrow at the root of the nose and widens as it passes up to the hairline. The donor site may be closed by a skin graft or by advancing the edges through laterally extending the superior incisions at the hairline.
- iii. Seagull flap⁵. See figure 6. This was devised by Millard for total nasal reconstruction (external lining only).
- iv. Laterally based inverted 'U'⁶. (see figures 3 and 4), and sickle shaped flaps can be designed to give extra length to the flap pedicle. The tip of such a flap can thus be folded in for alar lining and construction of the columella.

The plane of flap dissection lies beneath the galea

but the vessel(s) must be protected at the base of the flap.

The flap length siting of pedicle and design are based on indications. For coverage of small frontal defects, flap based on the medial side as in case 4 suffices. For nose reconstruction, larger flaps are required, the pedicle being tubed to minimise infection. For indications greater or further than nose reconstruction, the pedicle as in case 5 may be utilised for closure as much as possible. Most cases require a second stage for fashioning and excision of dog ear.

In closing flap donor site whose edges cannot be apposed directly, skin grafts should be used, some of which can be excised when the unused part of the flap is returned. Skin grafted flap donor sites often end up with mild donor site depressions. For patients with frontal baldness, the flap may be extended towards the vertex in which case the major feeding vessel will be the parietal branch of superficial temporal.

The forehead flap may be used for oral lining in cases of full thickness loss of the cheek and lip. Alternatives to forehead flap transfer in facial reconstruction may be found in the use of distant flaps either as staged pedicled transfer or as free flaps.

References

1. Conway H, Stark B, Kavanagh JD. Variations of the temporal flap. *Plast and Reconstruct. Surg.* 1952; 9: 410 - 423.
2. Corso PF. Variations of the arterial, venous and capillary circulation of the soft tissues of the head by decades as demonstrated by the methyl methacrylate injection technique, and their application to the reconstruction of flaps and pedicles. *Plast. and Reconstruct. Surg.* 1961; 27: 160 - 184.
3. Cormack GC. and Lamberty BGH. *The Arterial Anatomy of Skin Flaps.* Edingburgh: Churchill Livingstone. 1986. 384 - 403.
4. Sawhney CP. Use of larger midline forehead flap for rhinoplasty with new design for closure of donor site. *Plast. and Reconstruct. Surg.* 1979; 63: 395 - 397.
5. Millard DR. Jr. Reconstructive rhinoplasty for the lower half of the nose. *Plast. and Reconstruct. Surg.* 1974; 53: 133-139.
6. May H. The nose and Internasal regions. In *Plastic and reconstructive Sug.* F.A. Davies Company. Philadelphia 1971. E ed. 379 -448.