

Acute kidney injury secondary to iatrogenic bilateral ureteric ligation following emergency abdominal hysterectomy

Oluseyi A. Adejumo OA¹, Olurotimi S. Ogundiniyi², Ayodeji A. Akinbodewa AA¹,
Lawrence A. Adesunloro², Oladimeji J. Olafisoye¹

Abstract

Background: Bilateral ureteric injury, although rare is a complication that could follow obstetric, gynaecologic and other pelvic surgeries. Majority of cases are diagnosed postoperatively, hence a high index of suspicion is required in patients who develop acute kidney injury (AKI) following abdomino-pelvic surgeries. Early diagnosis and intervention is key in the reversal of this uncommon type of AKI

Methods: We reviewed the case notes of a 47 year old female who was managed for AKI following abdominal hysterectomy

Results: We present a case of 47 year old female who was referred to us 24 hours after she developed acute kidney injury following emergency abdominal hysterectomy on account of uterine rupture. There was significant haemorrhage before and during the surgery. Estimated glomerular filtration rate at presentation was 17 mls/min/1.73m² and abdominopelvic ultrasound showed bilateral obstructive uropathy. She received

blood transfusion, haemodialysis, explorative surgery where both ureters were found to be ligated with evidence of bilateral hydronephrosis within 72 hours of referral. Bilateral ureteroneocystostomy was done with subsequent complete renal recovery.

Conclusion: Ureteric injuries should always be considered in all patients who develop AKI following abdomino-pelvic surgeries even in the presence of other possible causes such as haemorrhage. Abdominopelvic ultrasound scan should be done in these patients and early referral for specialist care is key to reducing associated morbidity and mortality.

Key words: Bilateral ureteric injuries, acute kidney injury

Highland Med Res J 2016;16(1):42-44

Introduction

Urologic injuries following obstetric and gynaecological surgeries are rare and the reported incidence by Ghazi et al was as low as 1.8%.¹ These injuries include unilateral ureteric injuries, bilateral ureteric injuries, vesicovaginal fistula and bladder injuries. Ureteric injuries were reported to be the commonest urologic injury following hysterectomy.² Suture ligation is the commonest type of iatrogenic ureteric injury and affects the distal part in 75.6% of cases.³ Acute renal failure due to bilateral ureteric ligation is rare. Mate-Kole et al reported 7 cases over a 7 year period at Korle Bu Teaching Hospital Accra.⁴ Risk factors for these injuries include adhesions, previous abdominal surgeries, malignancies, previous irradiation and lack of experience of the surgeons.⁵

Most diagnosis were usually made postoperatively and may occur months after the surgery.⁶ Factors associated with mortality are delayed presentation,

deranged renal function, missed diagnosis and presence of post-operative complications such as infection.³ Surgical outcome is good in most cases, especially if diagnosis and intervention are timely.³

Case Presentation

A 47 year old female who was referred from a secondary health facility on account of anuria of a day duration following emergency hysterectomy. The indication for the hysterectomy was uterine rupture from prolonged obstructed labour. There was history of significant blood loss prior and during the surgery. She received three units of blood transfusion, intravenous fluids and furosemide without any improvement in her urinary output and was subsequently referred to our centre a day after her surgery.

She was found to be well hydrated but pale at presentation in our hospital with a packed cell volume of 14% despite transfusion at referral hospital. Renal function test at presentation was deranged with a urea of 9.0 mmol/L, creatinine of 303.6 micromol/L and estimated GFR of 17 mls/min/1.73m² using modification of diet in renal disease formula. The electrolytes were essentially normal. Urgent abdominopelvic ultrasound showed bilateral hydronephrosis and dilated ureters.

¹Kidney Care Centre, Ondo, Ondo State ²Ondo State Trauma Centre, Ondo State

All correspondences to:
Dr Adejumo Oluseyi A. Kidney Care Centre, Ondo
E-mail: ceeward2010@yahoo.com

She was co-managed with urology team who took her for emergency surgical exploration after haemodialysis and blood transfusion. She subsequently had bilateral ureteroneocystostomy with stenting. Intra-operative findings revealed ligation of both ureters with vicryl sutures near the ureterovesical junctions, and grossly dilated ureters bilaterally.(see Fig 1).

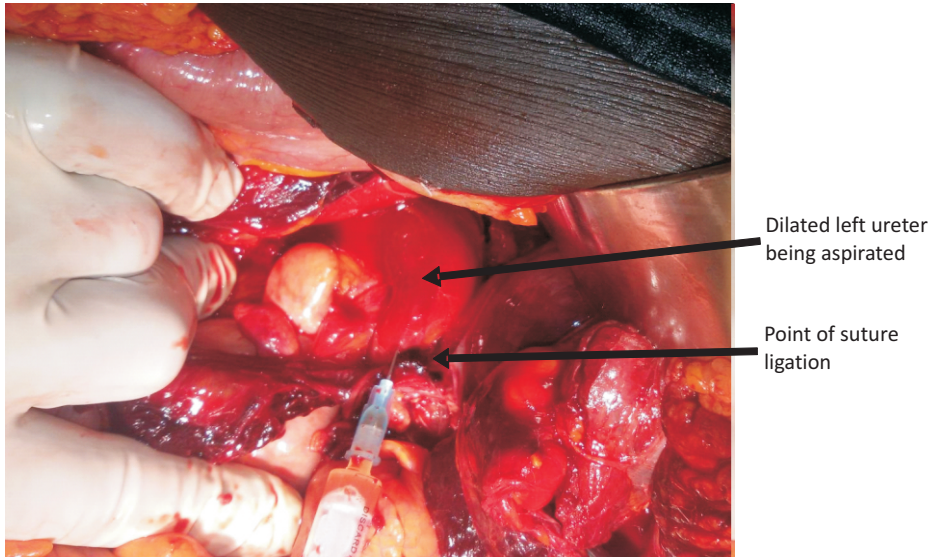


Fig 1: Showing dilated left ureter and point of suture ligation

At surgery, the dilated ureters were identified and traced to the point where they were suture ligated close to the vesico-ureteric junction. The ureters were transected above the level of ligation and mobilized while preserving their adventitia covering. The anterior wall of the urinary bladder was opened and intravesical re-implantation were performed. Two size 6 feeding tubes were used as ureteric stent and were attached to a size 18 two way Foley's catheter using a 3/0 nylon suture. The bladder was closed in two layers. The abdominal cavity was irrigated copiously with normal saline, a pelvic drain left in situ and the wound closed in layers.

There was immediate improvement in urinary output following surgery. This was sustained post-operatively with improvement in renal function biochemically. The pelvic drain was removed on post-operative day five, sutures removed on post-operative day ten and the urethral catheter with its attached stents on post-operative day fifteen. She had an uneventful post-operative course.

Discussion

Post renal cause of AKI is the least common of all types of AKI accounting for 10% of all cases of AKI,⁷ hence this could easily be missed especially in the presence of other possible aetiologies such as haemorrhage as seen in

this patient who had ante-partum haemorrhage from ruptured uterus. The haemorrhage might have contributed to the acute renal insult, but was not the cause of acute kidney injury in her, hence this was a red herring in this patient.

Ureteric injuries should always be considered in all patients who develop AKI following abdomino-pelvic surgeries, hence such patients should always have abdomino-pelvic ultrasound as early as possible. Radiologic evidences of urinary obstruction such as hydronephrosis and dilated ureters may not be evident as early as less than 24 hours following onset of acute obstruction especially in the presence of severe dehydration. Sensitivity of ultrasound for diagnosis of obstruction can be improved by measuring the resistive index with color doppler ultrasound. A resistive index above 0.7 reflects increased vascular resistance present in

obstruction and effectively discriminates between obstructed and non-obstructed kidneys.⁸

This index patient presented early about 24 hours after surgery with anuria which was the alarm sign, despite blood transfusion, fluid repletion and furosemide challenge. The anuria in this patient probably prompted the early referral. Mensah et al reported that diagnosis of ureteric injuries may be delayed for months, but usually early in those with bilateral ureteric injuries as seen in our patient.⁹

Severe haemorrhage is one of the established risk factors for ureteric injury which was present in this patient.⁵ Other possible risk factors were inadequate exposure from the pfannenstiel incision that was used for the surgery and the fact that the surgery was done as emergency. The ureteric injury in our patient was by suture ligation and involved the distal part. This was reported by Chalya et al as the commonest type and location of ureteric injury.³ The fact that the course of the ureters is posterior to the uterine arteries distally makes them prone to injuries while attempting to ligate the uterine arteries in order to secure haemostasis.

The patient had prompt surgical exploration by the urologist and bilateral ureteroneocystostomy and ureteric stenting were done with complete renal recovery. This surgical procedure is the most widely recommended for distal ureteric injuries.¹⁰ Our patient had good outcome because of the early referral, diagnosis and prompt surgical intervention.

Conclusion

Bilateral ureteric injury although rare should always be considered in patients who develop AKI following abdomino-pelvic surgeries even in the presence of other risk factors. Timely referral of such patients to nephrologist and urologist is key to the outcome of the patients and reduction in the global burden associated with AKI.

Acknowledgement: We wish to acknowledge this patient for granting us the permission to report her case as well as the contributions of Dr (Mrs) Bimpe Bello towards the timely management of this patient.

References

1. Ghazi A, Iqbal P, Saddique M. Bladder and ureter injuries during obstetric and gynaecological procedures. *Pak J Surg* 2008;24:53-56
2. Bouya PA, Odezebe AWS, Otiobanda FG et al. Les Complications Urologiques de la Chirurgie gynécologique. *Progres en Urologie* 2011;21:875-878
3. Chalya PL, Massinde AN, Kihunrwa A et al. Iatrogenic ureteric injuries following abdominopelvic operations: a 10-year tertiary hospital experience in Tanzania. *World J Emerg Surg* 2015;10:17
4. Mate-Kole MO, Yeboah ED, Affram RK et al. Anuric acute renal failure due to bilateral ureteric ligation during abdominal hysterectomy. *Int J Gynecol Obstet* 1993;41:67-73
5. Blandy JP, Badenoch DF, Fowler CG et al. Early repair of iatrogenic injury to ureter and bladder after gynaecological surgery. *J Urol* 1991;146:761-65
6. Hounnasso PP, Avakoudjo JG, Babadi N et al. Urologic complications after gynecologic and obstetric surgery at the urology-andrology teaching clinic of teaching hospital of Cotonou. *Open J Urol* 2014;4:121-125
7. Liano F, Junco E, Pascual J et al. The spectrum of acute renal failure compare with that seen in other setting. The Madrid Acute Renal Failure Study Group. *Kid Int Suppl* 1998;66:16-24
8. Mostbeck GH, Zontsich T, Turetschek K. Ultrasound of the kidney: Obstruction and medical diseases. *Eur Radiol.* 2001;11:1878-1889
9. Mensah JE, Klufio GO, Ahiaku F et al. Delayed recognition of bilateral ureteral injury after gynaecological surgery. *Ghana Med J* 2008;42:133-36
10. Burks FN, Santucci RA. Management of iatrogenic ureteral injury. *Ther Adv Urol* 2014;6:115-124